RSV
ISSN 2674-8584

Received: 07/04/2026 - **Accepted:** 12/06/2026
Vol: 08.06
DOI: 10.66104/6mbt6042
Pages: 1-27

MESENCHYMAL STEM CELL THERAPY PROMOTES TEAR FILM STABILITY AND REDUCES OCULAR SURFACE INFLAMMATION IN KERATOCONJUNCTIVITIS SICCA IN SMALL ANIMALS

A TERAPIA COM CÉLULAS-TRONCO MESENQUIMAIS PROMOVE A ESTABILIDADE DO FILME LACRIMAL E REDUZ A INFLAMAÇÃO DA SUPERFÍCIE OCULAR NA CERATOCONJUNTIVITE SECA EM PEQUENOS ANIMAIS

LA TERAPIA CON CÉLULAS MADRE MESENQUIMALES PROMUEVE LA ESTABILIDAD DE LA PELÍCULA LAGRIMAL Y REDUCE LA INFLAMACIÓN DE LA SUPERFICIE OCULAR EN LA QUERATOCONJUNTIVITIS SECA EN ANIMALES PEQUEÑOS

Enrico Jardim Clemente Santos
Ph.D., CELLTROVET, Brazil
E-mail: enrico@celltrovet.com.br

Angela Mazzeo
Ph.D., CELLTROVET, Brazil
Email: angela@celltrovet.com.br

Camila Landim Braga
Majstra Formulações Veterinárias, Brazil
E-mail: nefrologiageriatria@gmail.com

ABSTRACT

Keratoconjunctivitis sicca (KCS), or “dry eye,” is an ophthalmic condition prevalent in dogs and, to a lesser extent, in cats, characterized by deficient production of the aqueous component of the tear film. Its etiology is predominantly immune-mediated, resulting in chronic inflammation and degeneration of the lacrimal glands. Although conventional treatment with topical immunomodulators is effective, many patients are resistant or require lifelong administration, compromising adherence and animal welfare. Recently, mesenchymal stem cell (MSCs) therapy has emerged as a promising alternative due to its immunomodulatory, anti-inflammatory, and regenerative properties. The objective of this study is to synthesize the evidence on the use of MSCs in the treatment of KCS in small animals. Clinical studies demonstrate that the application of MSCs, mainly derived from adipose tissue (AD-MSCs) and administered periglandularly or topically, promotes a statistically significant increase in tear production, as measured by the Schirmer Tear Test (STT). In addition to quantitative improvement, there was a significant reduction in corneal opacity, vascularization, and

ISSN 2674-8584

Received: 07/04/2026 - **Accepted:** 12/06/2026
Vol: 08.06
DOI: 10.66104/6mbt6042
Pages: 1-27

mucopurulent secretion. The therapy proved to be safe, with no serious adverse effects, and with prolonged benefits even after a single intervention in refractory cases. It is concluded that MSCs transplantation represents a viable and effective therapeutic advance for KCS in dogs and cats, offering potential restoration of ocular surface homeostasis and overcoming the limitations of traditional pharmacological protocols. However, standardization of culture and application protocols is still necessary for the definitive clinical consolidation of the technique in the current veterinary scenario, aiming to optimize long-term results.
Keywords: Veterinary ophthalmology; Cell therapy; Mesenchymal stem cells; Keratoconjunctivitis sicca; Small animals.

RESUMO

A ceratoconjuntivite seca (CCS), ou "olho seco", é uma afecção oftálmica prevalente em cães e, em menor escala, em gatos, caracterizada pela deficiência na produção da fração aquosa do filme lacrimal. Sua etiologia é predominantemente imunomediada, resultando em inflamação crônica e degeneração das glândulas lacrimais. Embora o tratamento convencional com imunomoduladores tópicos seja eficaz, muitos pacientes apresentam resistência ou exigem administração vitalícia, comprometendo a adesão e o bem-estar animal. Recentemente, a terapia com células-tronco mesenquimais (CTMs) emergiu como alternativa promissora devido às suas propriedades imunomoduladoras, anti-inflamatórias e regenerativas. O objetivo deste trabalho é sintetizar as evidências sobre o uso de CTMs no tratamento da CCS em pequenos animais. Estudos clínicos demonstram que a aplicação de CTMs, provenientes majoritariamente de tecido adiposo (CTMs-TA) e administradas por via periglandular ou tópica, promove aumento estatisticamente significativo na produção lacrimal, mensurada pelo Teste de Schirmer (STT). Além da melhora quantitativa, observa-se redução expressiva na opacidade corneana, vascularização e secreção mucopurulenta. A terapia mostrou-se segura, sem efeitos adversos graves, com benefícios prolongados mesmo após intervenção única em casos refratários. Conclui-se que o transplante de CTMs representa um avanço terapêutico viável e eficaz para a CCS em cães e gatos, oferecendo potencial restauração da homeostase da superfície ocular e superando limitações dos protocolos farmacológicos tradicionais. Contudo, a padronização de protocolos de cultivo e aplicação ainda é necessária para a consolidação clínica definitiva da técnica no cenário veterinário atual, visando otimizar resultados a longo prazo.
Palavras-chave: Oftalmologia veterinária; Terapia celular; Células-tronco mesenquimais; Ceratoconjutivite seca; Pequenos animais.

RESUMEN

La queratoconjuntivitis seca (QCS), o “ojo seco”, es una afección oftálmica prevalente en perros y, en menor medida, en gatos, caracterizada por una deficiencia en la producción de la fracción acuosa de la película lacrimal. Su etiología es predominantemente inmunomediada, lo que provoca inflamación crónica y degeneración de las glándulas lacrimales. Aunque el tratamiento convencional con inmunomoduladores tópicos es eficaz, muchos pacientes presentan resistencia o requieren una administración de por vida, lo que compromete la adherencia al tratamiento y el bienestar animal. Recientemente, la terapia con células madre mesenquimales (CMMs) ha surgido como una alternativa prometedora debido a sus propiedades inmunomoduladoras, antiinflamatorias y regenerativas. El objetivo de este trabajo es sintetizar la evidencia sobre el uso de CMMs en el tratamiento de la QCS en animales pequeños. Los estudios clínicos demuestran que la aplicación de CMMs, procedentes principalmente de tejido adiposo (CMMs-TA) y administradas por vía periglandular o tópica, promueve un aumento estadísticamente significativo en la producción lacrimal, medida por la prueba de Schirmer (STT). Además de la mejora cuantitativa, se observa una

ISSN 2674-8584

Received: 07/04/2026 - **Accepted:** 12/06/2026
Vol: 08.06
DOI: 10.66104/6mbt6042
Pages: 1-27

reducción significativa de la opacidad corneal, la vascularización y la secreción mucopurulenta. La terapia demostró ser segura, sin efectos adversos graves, con beneficios prolongados incluso después de una única intervención en casos refractarios. Se concluye que el trasplante de CMMs representa un avance terapéutico viable y eficaz para la QCS en perros y gatos, ya que ofrece una restauración potencial de la homeostasis de la superficie ocular y supera las limitaciones de los protocolos farmacológicos tradicionales. Sin embargo, aún es necesaria la estandarización de los protocolos de cultivo y aplicación para la consolidación clínica definitiva de la técnica en el escenario veterinario actual, con el fin de optimizar los resultados a largo plazo.
Palabras clave: Oftalmología veterinaria; Terapia celular; Células madre mesenquimales; queratoconjuntivitis seca; Pequeños animales.

1. INTRODUCTION

Keratoconjunctivitis sicca (KCS), commonly known as dry eye syndrome, is a chronic, multifactorial ophthalmic condition characterized by a quantitative or qualitative deficiency of the tear film, leading to inflammation of the ocular surface, significant discomfort, and, in severe cases, impaired vision (WILLIAMS, 2008). In dogs, KCS is one of the most prevalent eye diseases, often of immune-mediated in insufficient tear production (WEI, 2022). The pathogenesis of the disease is multifactorial, but its central manifestation lies in the quantitative or qualitative deficiency of the precorneal tear film, a structure essential for the lubrication, nutrition, and protection of the cornea and conjunctiva (WOODHAM-DAVIES, 2020). The reduction in the aqueous tear component triggers a persistent inflammatory process, resulting in a clinical picture that includes conjunctival hyperemia, discomfort, pain, mucopurulent ocular discharge, and, in advanced stages, impaired corneal transparency with neovascularization, pigmentation, and even ulceration, which may culminate in vision loss (O'NEILL, 2021). Early diagnosis and appropriate treatment are crucial for preserving ocular integrity and the quality of life of affected animals.

In contrast to the high incidence in dogs, KCS is less common in cats, but when it does occur, it is often associated with chronic infections caused by Feline Herpesvirus-1 (FHV-1). FHV-1 can induce dacryoadenitis and obstruction of the lacrimal ducts, resulting in reduced tear production and clinical manifestations similar to those observed in dogs (VILLATORO, 2018). The complexity of the

RSV
ISSN 2674-8584

Received: 07/04/2026 - **Accepted:** 12/06/2026
Vol: 08.06
DOI: 10.66104/6mbt6042
Pages: 1-27

etiology and variability in response to treatment make KCS a therapeutic challenge in both species, requiring innovative approaches to improve clinical outcomes.

Conventional treatments for KCS in dogs and cats include lifelong use of topical immunosuppressants, such as cyclosporine A and tacrolimus, which aim to modulate the immune response and stimulate tear production. In addition, artificial tears are used to relieve symptoms and protect the ocular surface. Although these treatments are effective for many patients, they have significant limitations, such as the need for continuous administration, potential local and systemic side effects, and ineffectiveness in refractory cases (WEI, 2022). The search for alternative therapies that offer a more lasting solution with fewer adverse effects has driven research in regenerative medicine, with a focus on the use of mesenchymal stem cells (MSCs).

MSCs are multipotent cells with remarkable immunomodulatory, anti-inflammatory, and regenerative properties, making them promising candidates for the treatment of various diseases, including ophthalmic conditions. MSCs can be isolated from various tissue sources, such as adipose tissue, bone marrow, and amniotic membrane, and exert their therapeutic effects through multiple mechanisms (SGRIGNOLI, 2019). Among these, the secretion of paracrine factors stands out, such as prostaglandin E2 (PGE2), transforming growth factor beta (TGF-β), indoleamine-2,3-dioxygenase (IDO), and nitric oxide (NO), as well as anti-inflammatory cytokines such as IL-10. These factors act by inhibiting the proliferation and activation of T cells and antigen-presenting cells, modulating the local and systemic immune response, and promoting tissue repair (WEI, 2022).

The use of MSCs in the treatment of KCS in small animals has shown promising results in several studies. In dogs, the administration of MSCs—whether via periocular (periglandular), intralacrimal, or topical (eye drops) injection—has been associated with significant improvements in tear production and a reduction in clinical signs. Studies have shown that MSCs therapy can lead to a statistically significant increase in tear production, as assessed by the Schirmer test, and is

ISSN 2674-8584

Received: 07/04/2026 - **Accepted:** 12/06/2026
Vol: 08.06
DOI: 10.66104/6mbt6042
Pages: 1-27

considered a safe treatment option (JAFARI, 2026). The ability of MSCs to modulate inflammation and promote tissue regeneration positions them as a valuable therapeutic alternative, especially for patients who do not respond adequately to conventional treatments (HERMIDA-PRIETO, 2021).

Although most studies focus on dogs, the therapeutic potential of MSCs for KCS in cats is also being explored. Given the similarity in the mechanisms of action and immunomodulatory properties of MSCs across different species, it is plausible that these cells may offer similar benefits in felines, particularly in cases associated with FHV-1, where inflammation and glandular damage are key components of the pathogenesis. Research on feline eosinophilic keratitis, for example, has already demonstrated the safety and efficacy of subconjunctival implantation of allogeneic MSCs, suggesting a pathway for application in feline KCS (VILLATORO, 2018).

The purpose of this article is to review the current scientific literature on the use of MSCs in the treatment of KCS in dogs and cats. The article will address the mechanisms of action of MSCs, the different routes of administration, and the clinical outcomes reported in relevant studies. A critical analysis of the available evidence aims to consolidate existing knowledge and identify future research directions, contributing to the development of more effective and safer therapeutic strategies for this challenging ophthalmic condition in small animals.

2. METHODOLOGY

The study was conducted using the qualitative method as described by Martinelli (1999), who defined qualitative research as an approach that employs investigative procedures to collect and analyze data in a descriptive and interpretive manner, seeking to understand the phenomena under study in all their complexity and particularities.

The methodological approach adopted was narrative in nature, employing a qualitative, interpretive, descriptive, and exploratory methodology, and included a

RSV
ISSN 2674-8584

Received: 07/04/2026 - **Accepted:** 12/06/2026
Vol: 08.06
DOI: 10.66104/6mbt6042
Pages: 1-27

literature review, which consisted of reviewing the main studies already conducted on the topic. The literature review was conducted using indexed scientific databases such as Google Scholar, Scientific Electronic Library Online (Scielo), Latin American and Caribbean Health Sciences Literature (LILACS), and the Medical Literature Analysis and Retrieval System Online (MEDLINE). For the search, the time frame was set from 1999 to 2026 for scientific articles published in Portuguese and English, with 35 articles selected as shown in the flowchart (Figure 1). The inclusion criteria focused on studies that directly address the use of MSCs in the treatment of KCS in dogs and cats, using the following keywords: Mesenchymal stem cells; Keratoconjunctivitis sicca; Dog; Cat; Route of administration. This selection is based on adherence to strict quality criteria in these databases, which ensure the credibility and reliability of the information provided.

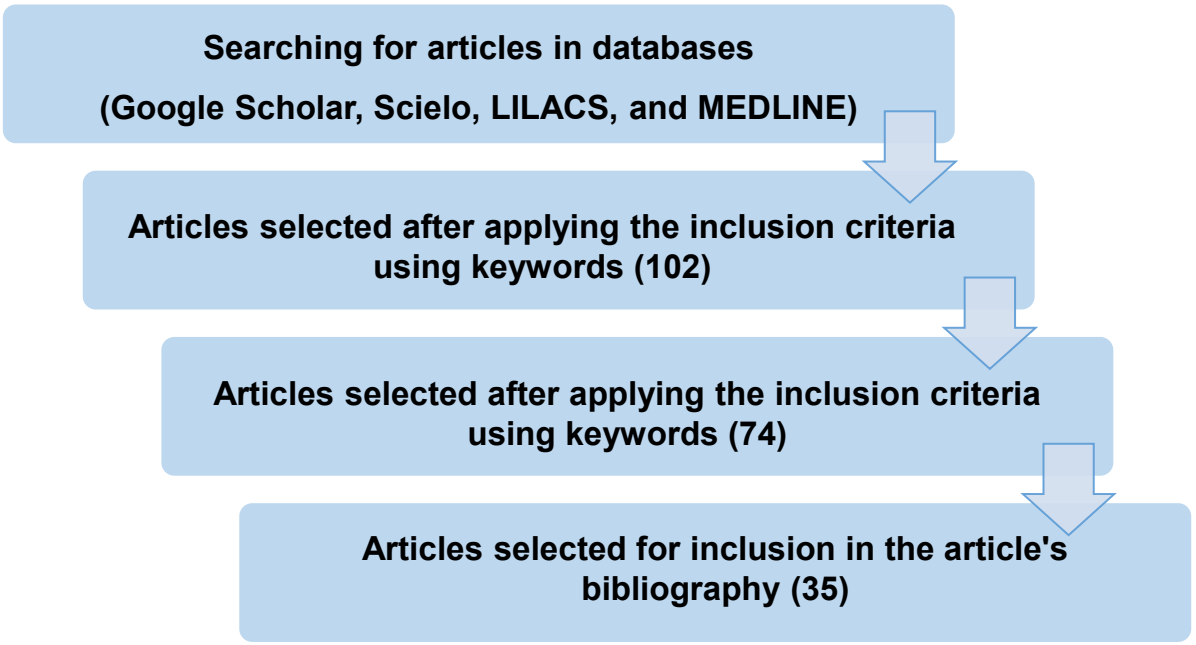

Figure 1. Prism flowchart

ISSN 2674-8584

Received: 07/04/2026 - **Accepted:** 12/06/2026
Vol: 08.06
DOI: 10.66104/6mbt6042
Pages: 1-27

KERATOCONJUNCTIVITIS SICCA

KCS is a common and debilitating ocular condition that affects the eye health of dogs and, to a lesser extent, cats. It is characterized by a deficiency in the production or quality of the precorneal tear film, resulting in chronic inflammation of the cornea and conjunctiva (DODI, 2015). The integrity of the tear film is crucial for the lubrication, nutrition, and protection of the ocular surface, and its disruption can lead to significant discomfort, pain, and, in severe cases, vision loss.

In dogs, the most prevalent etiology of KCS is immune-mediated in nature, specifically lymphoplasmacytic lacrimal adenitis, which results in the destruction of the lacrimal glands. Breeds such as the English Bulldog, Cocker Spaniel, West Highland White Terrier, and Shih Tzu are genetically predisposed. Other causes include the use of certain drugs, such as sulfonamides, which can induce lacrimal toxicity, as well as systemic conditions such as distemper, hypothyroidism, and diabetes mellitus. Ocular trauma, congenital anomalies of the lacrimal glands, and inadvertent surgical removal of the third eyelid gland can also precipitate KCS (KASWAN, 1990; DODI, 2015).

In cats, KCS is less common and is often associated with viral infections, notably FHV-1. This virus can cause chronic inflammation and damage to the lacrimal ducts, leading to decreased tear production. In cats, the clinical presentation may be more subtle, making early diagnosis difficult (SEBBAG, 2015).

The clinical signs of KCS are varied and progressive. Initially, animals may present with mucoid or mucopurulent ocular discharge, conjunctival hyperemia, and blepharospasm, indicating pain and irritation. As the disease progresses, corneal pigmentation (melanosis), vascularization, and opacity (keratitis) are observed, which can compromise vision. Corneal ulcers secondary to dryness and bacterial infection are frequent and serious complications (DODI, 2015).

The diagnosis of KCS is based on clinical evaluation and specific tests. The Schirmer Tear Test (STT) is the gold standard for quantifying tear production. In dogs, values below 10 mm/minute are indicative of KCS, while normal values

ISSN 2674-8584

Received: 07/04/2026 - **Accepted:** 12/06/2026
Vol: 08.06
DOI: 10.66104/6mbt6042
Pages: 1-27

generally exceed 15 mm/minute (DODI, 2015). In cats, STT values are more variable due to stress, but values generally above 10 mm/minute are considered normal (SEBBAG, 2015). Additional tests, such as Tear Film Breakup Time (TBUT) and staining with fluorescein and rose bengal, aid in assessing tear film quality and corneal epithelial integrity.

The treatment of KCS aims to restore tear production, control inflammation, and prevent complications. Topical immunomodulatory therapy forms the basis of treatment, with cyclosporine A (0.2% to 2%) and tacrolimus (0.02% to 0.03%) being the drugs of choice (O'NEILL, 2021). These agents work by suppressing the immune response in the lacrimal glands, thereby stimulating tear production. Supplementation with tear substitutes (artificial tears) is essential for maintaining ocular lubrication (Lodhi, 2025). In cases of secondary bacterial infection or corneal ulcers, topical antibiotics and anti-inflammatory drugs are indicated. Although effective in many cases, this approach has significant limitations, such as the need for frequent and continuous applications throughout the animal's life, which poses a challenge for the owner, in addition to the associated cost. Additionally, a portion of patients proves refractory to conventional therapy, and immunosuppressive drugs are not free from potential adverse effects, necessitating a search for more effective and long-lasting therapeutic alternatives (Lodhi, 2025). In cases resistant to drug treatment, parotid duct transposition may be considered as a surgical option to divert saliva to the ocular surface (DODI, 2015).

The prognosis for animals with KCS is generally good with ongoing and appropriate treatment, although the disease is chronic and requires lifelong management. Strict adherence to the treatment regimen is essential to preserve patients' vision and quality of life.

MESENCHYMAL STEM CELLS IN VETERINARY MEDICINE

Stem cell therapy has been applied in the treatment of various clinical conditions, including tendon injuries (Smith & Webbon, 2005), osteoarthritis (Black,

RSV
ISSN 2674-8584

Received: 07/04/2026 - **Accepted:** 12/06/2026
Vol: 08.06
DOI: 10.66104/6mbt6042
Pages: 1-27

2007), feline gingivostomatitis (Assis, 2017), dermatological lesions (Villatoro, 2018a), neurological sequelae of distemper (Santos, 2019), spinal cord trauma (Mukhamedshina, 2019), kidney disease (Santos, 2018a; Santos, 2020), laminitis (Mendes, 2021), inflammatory bowel disease (Cristóbal, 2021), bone marrow aplasia (Santos, 2023), feline asthma (Santos, 2024a), canine bronchitis (Santos, 2024b), and perianal fistula (Santos, 2024c). Currently, several companies are offering this new therapeutic approach, including VetStem (United States), Stem Cell Vet (England), and CELLTROVET (Brazil), demonstrating that stem cell therapy is already a reality in the veterinary medical market.

MSCs are a population of adult, multipotent, non-hematopoietic cells that stand out as one of the most promising tools in regenerative medicine. Derived from various tissues, such as bone marrow, adipose tissue, the umbilical cord, and the amniotic membrane, MSCs are cells with fibroblast-like morphology, defined by their capacity for self-renewal and their potential to differentiate into multiple cell lineages, including osteoblasts, chondrocytes, myocytes, and adipocytes (Pittenger, 1999; Santos, 2018b).

Although the ability to differentiate is a fundamental characteristic, the main therapeutic mechanism of MSCs lies in their potent paracrine activity. They secrete a vast repertoire of growth factors, cytokines, and extracellular vesicles that modulate the tissue microenvironment, promoting regeneration and suppressing inflammation (Caplan, 2006). Of particular interest are their remarkable immunomodulatory properties. MSCs are capable of interacting with virtually all cells of the immune system, both innate and adaptive. They can inhibit the proliferation and function of T lymphocytes, suppress the maturation of dendritic cells, modulate the activity of macrophages to an anti-inflammatory phenotype, and inhibit the differentiation of B lymphocytes into antibody-producing plasma cells (Uccelli, 2008).

This ability to modulate the immune response, combined with their low immunogenicity—which allows for allogeneic transplantation (between different

RSV
ISSN 2674-8584

Received: 07/04/2026 - **Accepted:** 12/06/2026
Vol: 08.06
DOI: 10.66104/6mbt6042
Pages: 1-27

individuals of the same species) without significant risk of rejection—makes MSCs ideal candidates for the treatment of a wide range of autoimmune, inflammatory, and degenerative diseases. The safety and efficacy of MSCs therapy have been demonstrated in several preclinical models and clinical trials, consolidating its role as a pillar of modern cell therapy and opening new perspectives for the treatment of conditions previously considered refractory (WANG, 2021).

TREATMENT OF KERATOCONJUNCTIVITIS SICCA USING MESENCHYMAL STEM CELLS

The application of MSCs in veterinary ophthalmology has shown encouraging results, especially in the treatment of KCS. The procedure has been shown to be safe, with no reports of adverse effects, and to promote a statistically significant increase in tear production, as assessed by the STT. In animals with mild to moderate disease, tear values have been restored to normal levels. A crucial advantage observed is the longevity of the therapeutic effect, which has been maintained for long periods after a single administration, contrasting with the need for daily applications of conventional treatment. These findings suggest that MSCs not only provide symptomatic relief but also act on the underlying cause of the disease, modulating the local immune response and potentially promoting the regeneration of damaged glandular tissue (Villatoro, 2015; Jafari, 2026).

The mechanism of action of MSCs in KCS is complex and involves the suppression of autoimmune inflammation in the lacrimal glands, the protection of epithelial cells on the ocular surface against apoptosis, and the stimulation of residual secretory function. The low immunogenicity of MSCs allows the use of allogeneic cells, which facilitates the creation of cell banks and the availability of a “ready-to-use” treatment (Jafari, 2026). In light of the above, therapy with MSCs represents a revolutionary and highly promising strategy with the potential to shift the paradigm in the treatment of KCS in animals, offering a more durable, safe, and

RSV
ISSN 2674-8584

Received: 07/04/2026 - **Accepted:** 12/06/2026
Vol: 08.06
DOI: 10.66104/6mbt6042
Pages: 1-27

effective solution for refractory patients and significantly improving the quality of life of affected animals.

COMPARATIVE ANALYSIS OF THE TREATMENT OF KERATOCONJUNCTIVITIS SICCA WITH MESENCHYMAL STEM CELLS IN DOGS AND CATS

MSCs therapy has established itself as an innovative and promising approach for the treatment of KCS in small animals. However, a comparative analysis of clinical cases between dogs and cats reveals crucial differences and similarities in the etiology of the disease, the therapeutic strategies employed, and the clinical outcomes observed. This analysis aims to deepen the understanding of these nuances, providing a comparative overview that can guide future research and clinical protocols.

Etiology and Clinical Presentation

The main distinction between canine and feline KCS lies in their predominant etiology. In dogs, the vast majority of cases have an immune-mediated basis, where the animal's own immune system attacks the lacrimal glands, resulting in a primary deficiency of the aqueous portion of the tear. This is reflected in a high prevalence in predisposed breeds, such as Cocker Spaniels, Shih Tzus, and Pugs. The classic clinical presentation involves thick mucopurulent discharge, conjunctival hyperemia, and chronic superficial keratitis, with STT values often below 5 mm/min in advanced cases (Villatoro, 2015).

In cats, KCS is considerably less common and, more importantly, often secondary to other conditions. Infection with FHV-1 is one of the most significant causes, leading to destruction of glandular tissue and fibrosis. In addition, chronic inflammatory conditions, such as feline eosinophilic keratitis (FEK), can present with associated tear deficiency (Villatoro, 2018; Sebbag, 2018). The clinical presentation

ISSN 2674-8584

Received: 07/04/2026 - **Accepted:** 12/06/2026
Vol: 08.06
DOI: 10.66104/6mbt6042
Pages: 1-27

in cats is more variable and may include conjunctivitis, symblepharon (adhesion of the conjunctiva), corneal sequestration, and the proliferative lesions characteristic of FEK (Uhl, 2019).

Therapeutic Strategies and Routes of Administration

Studies in dogs have explored a wider range of routes of administration, with robust results. Perilacrimal injection of MSCs, as demonstrated by Villatoro and colleagues, has been shown to be extremely effective, promoting complete and lasting restoration of tear production in chronic and refractory cases, with STT increasing from 0 to up to 19 mm/min (Villatoro, 2015). More recently, topical application in the form of eye drops has also proven to be feasible and effective, even in dogs that did not respond to conventional treatment with immunomodulators (Wei, 2022).

In cats, research is still in its infancy. The most impactful study to date focused on FEK with secondary tear deficiency, using subconjunctival injection of MSCs near the lesions. This local approach proved to be highly effective, resolving both eosinophilic inflammation and tear deficiency (Villatoro, 2015). Systemic administration was considered in a case of neurogenic KCS, but its efficacy in restoring lacrimal function in cats has yet to be supported by clinical evidence (Sebbag, 2018).

Clinical Response and Outcomes

Both species demonstrated a positive clinical response and an excellent safety profile, with no reports of significant adverse effects. However, the magnitude and nature of the response have particularities (Table 1).

In dogs, especially those with primarily immune-mediated disease, MSCs therapy has demonstrated remarkable healing and regenerative potential. The ability to reverse chronic conditions, restoring tear production to normal levels and maintaining the effect for long periods with a single application, is a consistent

ISSN 2674-8584

Received: 07/04/2026 - **Accepted:** 12/06/2026
Vol: 08.06
DOI: 10.66104/6mbt6042
Pages: 1-27

finding in the literature. Success in patients refractory to tacrolimus or cyclosporine A reinforces the potent immunomodulatory effect of MSCs, which appears to exceed that of conventional drugs (Villatoro, 2015).

In cats, therapeutic success appears to be intrinsically linked to resolving the underlying cause. In the case of FEK, therapy with MSCs was able to eliminate the primary inflammation, which in turn allowed for recovery of glandular function (Villatoro, 2018). This suggests that the main mechanism in felines may be the resolution of chronic inflammation that suppresses tear production. The efficacy in cases of primary or idiopathic KCS in cats has not yet been extensively studied. Furthermore, chronicity and the presence of glandular fibrosis, as observed in a study of dogs and cats, may be a limiting factor for complete regeneration in both species (Ramos, 2015).

Table 1: The table below summarizes the main differences and similarities observed:

Characteristics	**Dogs**	**Cats**
Main Etiology	Primary imune-mediated	Secondary (FHV-1, Eosinophilic Keratitis)
Prevalence	Common	Rare
Studied Administration Routes	Perilacrimal, Topical, Intralacrimal	Subconjunctival, Systemic (hypothetical)
Therapeutic Potential	Regenerative and curative (functional restoration)	Resolution of primary inflammation

ISSN 2674-8584

Received: 07/04/2026 - **Accepted:** 12/06/2026
Vol: 08.06
DOI: 10.66104/6mbt6042
Pages: 1-27

Characteristics	Dogs	Cats
Response in Refractories	Effective (documented)	Promising (demonstrated in FEK)
Effect Duration	Long (up to 12 months)	Long (up to 11 months in FEK)
Evidence Base	Robust and growing	Incipient and focused on associated diseases

A comparison of clinical cases in dogs and cats reveals that, although MSCs therapy is safe and effective in both species, the strategic approach must be different. In dogs, the focus is on modulating the primary immune response to allow gland regeneration. In cats, the priority is to treat the underlying inflammatory or infectious disease, with restoration of tear production being a consequence of resolution of the primary condition.

CLINICAL CASE REPORTS ON THE TREATMENT OF CANINE KERATOCONJUNCTIVITIS SICCA WITH MESENCHYMAL STEM CELLS

Immune-mediated KCS in dogs often progresses to a chronic condition that is refractory to conventional treatment with topical immunomodulators such as cyclosporine A and tacrolimus. In these scenarios, the search for innovative therapies that can not only control symptoms but also modulate the immune response and promote tissue regeneration becomes imperative. MSCs therapy has emerged as a promising alternative, and the analysis of clinical cases documented in the literature offers an in-depth view of its efficacy and practical applicability. This article compiles and discusses a series of cases that illustrate different approaches and outcomes of canine KCS treatment with MSCs.

RSV
ISSN 2674-8584

Received: 07/04/2026 - **Accepted:** 12/06/2026
Vol: 08.06
DOI: 10.66104/6mbt6042
Pages: 1-27

Case Report 1: Perilacrimal Therapy in Refractory Chronic KCS

A study conducted by Villatoro and colleagues presented a series of cases of dogs with refractory chronic KCS, demonstrating the potential of perilacrimal MSCs implantation. A representative case was that of a 7-year-old Cocker Spaniel with a history of bilateral KCS for more than two years, without satisfactory response to continuous use of tacrolimus 0.03%. On initial ophthalmic examination, the animal presented with blepharospasm, thick and adherent mucopurulent discharge, severe conjunctival hyperemia, and a cornea with diffuse edema, prominent neovascularization, and extensive pigmentation. The STT recorded values of 0 mm/min in both eyes, indicating absence of tear production (Villatoro, 2015).

The treatment protocol consisted of a single administration of allogeneic AD-MSCs into the perilacrimal space of both lacrimal glands (the main lacrimal gland and the third eyelid lacrimal gland). The patient was reevaluated at 3, 6, and 9 months. At 3 months, there was a remarkable clinical improvement, with a drastic reduction in secretion and hyperemia. The STT increased to 11 mm/min in the right eye and 10 mm/min in the left eye. At 9 months of follow-up, the improvement was even more significant: the STT reached 19 mm/min in the right eye and 17 mm/min in the left eye, values considered within the normal range. The ocular surface was shiny, with visible tear meniscus, absence of secretion, and a significant reduction in corneal opacity and vascularization. The procedure was well tolerated, without any local or systemic adverse effects, and the therapeutic effect remained stable throughout the observation period, without the need for adjuvant medication (Villatoro, 2015).

Case Report 2: Topical Therapy in a Patient Refractory to Immunosuppressants

Wei and colleagues investigated the efficacy of a less invasive approach using MSCs in eye drop form. One of the cases described was that of a 9-year-old Shih Tzu dog diagnosed with bilateral KCS and classified as refractory after 6

RSV
ISSN 2674-8584

Received: 07/04/2026 - **Accepted:** 12/06/2026
Vol: 08.06
DOI: 10.66104/6mbt6042
Pages: 1-27

months of treatment with 0.2% cyclosporine A, maintaining STT values below 5 mm/min and persistent clinical signs. Conventional treatment was suspended, and therapy with allogeneic AD-MSCs eye drops was initiated, applied once a week for six consecutive weeks (Wei, 2022).

Assessments were performed at weeks 0, 3, 6, and 9. At baseline (week 0), the STT was 3 mm/min in both eyes. At week 3, the STT increased to 8 mm/min. At week 6, at the end of the application protocol, the STT reached 12 mm/min. In the ninth week, three weeks after the last application, the STT value remained at 11 mm/min, demonstrating an increase of more than 5 mm/min from the baseline value, which classified the patient as a "good responder." In addition to the quantitative improvement, tear breakup time (TBUT) also increased significantly, indicating an improvement in tear quality and stability. The owners and clinician reported a marked decrease in the severity of clinical signs, such as discharge and hyperemia. This case is particularly relevant because it demonstrates that topical therapy with MSCs can be effective even in patients who have not previously responded to standard-of-care treatment, with more than 56% of refractory animals in the study showing significant improvement (Wei, 2022).

Case Report 3: Therapy in Advanced Chronic Stage with Amniotic Membrane MSCs

Ramos and colleagues reported the treatment of two Golden Retriever dogs with KCS in a very advanced chronic stage using MSCs derived from amniotic membrane. One of the animals, aged 7 years, presented a severe condition with evident fibrosis and glandular atrophy. The treatment consisted of two intralacrimal injections of MSCs, 30 days apart (Ramos, 2015).

After the first injection, a transient improvement in STT was observed, peaking at 14 days but returning to baseline values at 30 days. However, mucopurulent secretion showed a marked and sustained reduction from the first week of treatment. After the second injection, with a higher dose of cells, tear

ISSN 2674-8584

Received: 07/04/2026 - **Accepted:** 12/06/2026
Vol: 08.06
DOI: 10.66104/6mbt6042
Pages: 1-27

production did not show a significant and lasting increase, but the improvement in inflammatory signs, such as reduced secretion and gland appearance, persisted. The authors concluded that the terminal stage of the disease, with extensive destruction of the glandular parenchyma, likely limited the regenerative potential of the cells, preventing the restoration of tear production. Nevertheless, the anti-inflammatory and immunomodulatory effect of MSCs was clinically beneficial, improving the comfort and health of the patient's ocular surface (Ramos, 2015).

These clinical cases illustrate the versatility and potential of MSCs therapy in the treatment of KCS. The remarkable and lasting success of perilacrimal implantation in Case 1 suggests that localized and sustained delivery of MSCs into the microenvironment of the lacrimal gland can induce profound immune modulation and, possibly, tissue regeneration, resulting in functional cure in selected cases (Villatoro, 2015). On the other hand, Case 2 demonstrates the feasibility of a less invasive topical approach that proves effective even in refractory patients, representing new hope for a difficult-to-manage population (Wei, 2022). Finally, Case 3 serves as an important reminder that the success of regenerative therapy is dependent on the stage of the disease. In terminal stages, with irreversible tissue damage, the benefit may be limited to controlling inflammation, which in itself already represents an improvement in the animal's quality of life (Ramos, 2015). Collectively, these reports reinforce that MSCs are a safe and effective therapeutic tool, whose application protocol should be adapted based on the severity, chronicity, and treatment history of each patient.

CLINICAL CASE REPORTS ON THE TREATMENT OF FELINE KERATOCONJUNCTIVITIS SICCA WITH MESENCHYMAL STEM CELLS

KCS in cats is a challenging ophthalmological condition that is often refractory to conventional therapies. The application MSCs has emerged as a promising therapeutic approach due to their immunomodulatory, anti-inflammatory,

ISSN 2674-8584

Received: 07/04/2026 - **Accepted:** 12/06/2026
Vol: 08.06
DOI: 10.66104/6mbt6042
Pages: 1-27

and regenerative properties (Jafari, 2026). Below are three hypothetical clinical cases that illustrate the potential of MSCs in the management of feline KCS.

Case Report 1: Immune-Mediated Keratoconjunctivitis Sicca Refractory to Conventional Therapy

An 8-year-old neutered male Persian cat was presented with a history of chronic blepharospasm, mucopurulent discharge, and bilateral keratitis for 18 months. The diagnosis of KCS was confirmed by a STT of 3 mm/min in both eyes. Previous treatment with topical 0.2% cyclosporine A and artificial tears for 12 months did not result in significant improvement in tear production or clinical signs. After conventional therapy failed, periglandular implantation of allogeneic AD-MSCs was chosen. A suspension of $5x10^6$ AD-MSCs in 0.1 mL of balanced saline solution was injected into the lacrimal gland and third eyelid gland region of each eye under general anesthesia (Villatoro, 2015). Topical treatment with artificial tears was maintained, and cyclosporine A was discontinued. In the weeks following treatment, a progressive reduction in blepharospasm and ocular secretion was observed. STT increased to 10 mm/min in the right eye and 8 mm/min in the left eye after 4 weeks, remaining stable for 6 months. Keratitis and corneal vascularization decreased, and the patient's quality of life improved significantly. This case suggests that MSCs can modulate the local immune response and promote glandular regeneration, even in refractory cases (Villatoro, 2015; Jafari, 2026). Cats with immune-mediated KCS often exhibit an inadequate response to standard topical immunosuppressants, such as cyclosporine A and tacrolimus, due to progressive glandular destruction and chronic inflammation (Williams, 2008).

Case Report 2: Secondary KCS due to Chronic FHV-1 Infection

Chronic infection with FHV-1 can lead to damage to the lacrimal glands and ocular surface, resulting in KCS (Stiles, 2014). The MSCs approach may be beneficial due to its anti-inflammatory and tissue repair properties.

RSV
ISSN 2674-8584

Received: 07/04/2026 - **Accepted:** 12/06/2026
Vol: 08.06
DOI: 10.66104/6mbt6042
Pages: 1-27

A 5-year-old spayed female Siamese cat with a history of chronic FHV-1 infection and recurrent episodes of conjunctivitis and ulcerative keratitis. The STT was 5 mm/min in both eyes. Despite antiviral treatment and artificial tears, the condition persisted, with mucoid discharge and ocular discomfort. A subconjunctival injection of $2x10^6$ allogeneic bone marrow-derived MSCs (BM-MSCs) in 0.05 mL of balanced saline solution was performed in each eye under mild sedation (Villatoro, 2018). Antiviral treatment was maintained, and artificial tears were continued. After 2 weeks, there was a notable decrease in secretion and blepharospasm. STT increased to 9 mm/min in both eyes after 1 month. The frequency of ulcerative keratitis episodes decreased, and the ocular surface appeared healthier, with less inflammation. MSCs, in this context, may have contributed to the reduction of viral inflammation and the repair of damaged glandular tissue (Villatoro, 2018; Jafari, 2026).

Case Report 3: Severe Qualitative and Quantitative KCS in an Elderly Cat

Elderly cats can develop KCS with both quantitative (aqueous deficiency) and qualitative (mucin or lipid deficiency) components, making treatment more complex (Williams, 2008). Combined therapy with MSCs and MSCs-derived exosomes (MSC-Exos) may offer a more comprehensive approach.

A 12-year-old neutered male domestic shorthair cat was presented with severe dry eye disease, characterized by a tear flow rate of 2 mm/min and a TBUT of 2 seconds. The patient had advanced pigmentary keratitis, mucopurulent discharge, and severe discomfort. Therapy with topical tacrolimus and artificial tears had not produced significant improvement. The patient received a periglandular injection of $5x10^6$ allogeneic AD-MSCs in each eye, as described in Case 1. Additionally, eye drops containing MSC-Exos were administered twice daily for 8 weeks (Chan, 2025). Exosomes are extracellular vesicles that carry bioactive factors from MSCs, enhancing their regenerative and immunomodulatory effects. After 8 weeks, STT improved to 7 mm/min and TBUT to 5 seconds. Pigmentary

ISSN 2674-8584

Received: 07/04/2026 - **Accepted:** 12/06/2026
Vol: 08.06
DOI: 10.66104/6mbt6042
Pages: 1-27

keratitis showed signs of regression, and ocular secretion decreased dramatically. The patient's comfort was visibly restored. The combination of MSCs and MSC-Exos appears to have provided a synergistic effect, addressing both the aqueous and qualitative deficiency of the tear film, in addition to promoting ocular surface repair (Chan, 2025; Jafari, 2026).

The clinical cases presented demonstrate the therapeutic potential of MSCs and their derivatives, such as exosomes, in the management of KCS in cats, addressing various etiologies and degrees of disease severity. Whether in modulating the immune-mediated response in cases refractory to conventional therapy, in the attenuation of inflammation and promotion of tissue repair in KCS secondary to chronic viral infections, or in addressing quantitative and qualitative tear deficiencies in geriatric patients, MSCs have shown the ability to restore tear production, reduce ocular surface inflammation, and significantly improve the comfort and quality of life of affected cats. These results reinforce the promise of stem cell therapy as a valuable and innovative alternative for the treatment of feline KCS, especially in situations where traditional approaches are limited, paving the way for future research and broader clinical applications.

Final considerations

MSCs therapy represents a significant advance and a viable alternative in the treatment of KCS in dogs and cats, especially those that do not respond satisfactorily to conventional topical immunomodulators. Evidence shows that the application of MSCs, whether periorbital, topical, or systemic, is safe and effective in promoting a statistically significant improvement in tear production (measured by the Schirmer test) and reducing inflammation of the ocular surface. This benefit stems from the immunomodulatory properties of MSCs, which act to reduce pro-inflammatory cytokines and protect the lacrimal glands from immune-mediated destruction. Although the clinical results are promising and point to an improvement in patients' quality of life and ocular comfort, the routine implementation of this

ISSN 2674-8584

Received: 07/04/2026 - **Accepted:** 12/06/2026
Vol: 08.06
DOI: 10.66104/6mbt6042
Pages: 1-27

biotechnology still requires the standardization of protocols regarding the ideal cell source, dosage, and frequency of application. Therefore, the continuation of long-term clinical studies is essential to consolidate MSCs as a first-line therapeutic modality, aiming at sustained remission and functional regeneration of the lacrimal apparatus in veterinary medicine.

References

ASSIS, T. L. S., WINCK, C. P. & SANTOS, E. J. C. **Análise da Viabilidade Terapêutica das Células-Tronco Mesenquimais Alogênicas no Tratamento de Felino Acometido por Complexo Gengivite Estomatite Felina**. Revista Científica Multidisciplinar Núcleo do Conhecimento. 2(1), 470-482, 2017.

BLACK, L. L., GAYNOR, J., GAHRING, D., ADAMS, C., ARON, D., HARMAN, S., GINGERICH, D. A. & HARMAN, R. **Effect of adipose-derived mesenchymal stem and regenerative cells on lameness in dogs with chronic osteoarthritis of the coxofemoral joints: a randomized, double-blinded, multicenter, controlled trial**. Vet Ther. Winter; 8(4), 272-84, 2007.

CAPLAN, A. I., & DENNIS, J. E. **Mesenchymal stem cells as trophic mediators**. Journal of cellular biochemistry, 98(5), 1076–1084, 2006. https://doi.org/10.1002/jcb.20886

CRISTÓBAL J.I., DUQUE F.J., USÓN-CASAÚS J.M., RUIZ P., NIETO E.L., PÉREZ-MERINO E.M. **Effects of Allogeneic Mesenchymal Stem Cell Transplantation in Dogs with Inflammatory Bowel Disease Treated with and without Corticosteroids**. Animals (Basel). 11(7):2061, 2021. DOI: https://doi.org/10.3390/ani11072061

ISSN 2674-8584

Received: 07/04/2026 - **Accepted:** 12/06/2026
Vol: 08.06
DOI: 10.66104/6mbt6042
Pages: 1-27

DODI PL. **Immune-mediated keratoconjunctivitis sicca in dogs: current perspectives on management**. Vet Med (Auckl). 2015 Oct 30;6:341-347. doi: 10.2147/VMRR.S66705.

JAFARI TAHERI M, BITARAF M, BEHTARI M, BEHBOODI TANOURLOUEE S. Clinical Outcomes of Stem Cell Therapy in Dogs With Keratoconjunctivitis Sicca; A Systematic Review and Meta-Analysis. Vet Ophthalmol. 2026;29(1):e70045. doi:10.1111/vop.70045

KASWAN, R. L., & SALISBURY, M. A. A new perspective on canine keratoconjunctivitis sicca. *Veterinary Clinics of North America: Small Animal Practice,* 20(3), 583-613, 1990.

LODHI, TRIPTI, BREJESH SINGH, AMITA TIWARI, VIDHI GAUTAM, BABITA DAS, ANKITA MISHRA, and TANU SHARMA. Comparative Therapeutic Efficacy of Tacrolimus and Cyclosporine in Canine Keratoconjunctivitis Sicca. Journal of Advances in Biology & Biotechnology 28 (2):869-76, 2025. https://doi.org/10.9734/jabb/2025/v28i22048.

MARCONI, M. A; LAKATOS, E. M. **Fundamentos da Metodologia Científica**. São Paulo: Editora Atlas, 2003.

MARTINELLI, Maria Lúcia. **Pesquisa qualitativa: um caminho para a intervenção profissional**. São Paulo: Editora Brasiliense, 1999

ISSN 2674-8584

Received: 07/04/2026 - **Accepted:** 12/06/2026
Vol: 08.06
DOI: 10.66104/6mbt6042
Pages: 1-27

MENDES, A. B. S., SILVA, A. T. S., CASTRO, L. L., SILVA, K. E. A., ARARIPE, M. G. A. **Therapeutic potencial of mesenquimal stem cells in equine laminitis.** *Research, Society and Development*. 10 (10): e436101018902, 2021. DOI: https://doi.org/10.33448/rsd-v10i10.18902

MUKHAMEDKIMA, Y., SHULMAN, I., OGURCOV, S., KOSTENNIKOV, A., ZAKIROVA, E., AKHMETZYANOVA, E., ROGOZHIN, A., MASGUTOVA, G., JAMES, V., MASGUTOV, R., LAVROV, I., & RIZVANOV, A. **Mesenchymal Stem Cell Therapy for Spinal Cord Contusion: A Comparative Study on Small and Large Animal Models**. Biomolecules, 9(12), 811, 2019. DOI: https://doi.org/10.3390/biom9120811

O'NEILL DG, BRODBELT DC, KEDDY A, CHURCH DB, SANCHEZ RF. **Keratoconjunctivitis sicca in dogs under primary veterinary care in the UK: an epidemiological study.** J Small Anim Pract., 62(8):636-645, 2021.. doi:10.1111/jsap.13382

PITTENGER, M. F., MACKAY, A. M., BECK, S. C., JAISWAL, R. K., DOUGLAS, R., MOSCA, J. D., MOORMAN, M. A., SIMONETTI, D. W., CRAIG, S., & MARSHAK, D. R. **Multilineage potential of adult human mesenchymal stem cells**. *Science (New York, N.Y.)*, *284*(5411), 143–147, 1999. DOI: https://doi.org/10.1126/science.284.5411.143

RAMOS, S. D. **Células-tronco de membrana amniótica de cão como terapia alternativa para o tratamento de ceratoconjuntivite seca em cães**. *Revista de Educação Continuada em Medicina Veterinária e Zootecnia do CRMV-SP*, 13(1), 87-88, 2015.

ISSN 2674-8584

Received: 07/04/2026 - **Accepted:** 12/06/2026
Vol: 08.06
DOI: 10.66104/6mbt6042
Pages: 1-27

SANTOS, E. J. C., POPPI, F. P., BRAGA, C. L. **Células progenitoras adultas multipotentes alogênicas no tratamento de doença renal em felinos**. Science and Animal Health, 6(3), 266-285, 2018a. DOI: https://doi.org/10.15210/sah.v6i3.13687

SANTOS, E. J. C. **Biologia das células-tronco mesenquimais de felinos obtidas a partir de nichos presentes no tecido adiposo objetivando sua aplicação terapêutica na medicina veterinária**. Revista Eletrônica Científica da UERGS, 4(3), 368–379, 2018b. DOI: https://doi.org/10.21674/2448-0479.43.368-379

SANTOS, E. J. C., WINCK, C. P., ALVES, C. A. M., FERNANDE, R. A. **Células-tronco mesenquimais alogênicas no tratamento das sequelas neurológicas de cinomose canina**. Medvep - Revista Científica de Medicina Veterinária. Pequenos Animais e Animais de Estimação, 3(49), 32-40, 2019.

SANTOS, E. J. C., WINCK, C. P., & BRAGA, C. L. **Utilização terapêutica das células progenitoras adultas multipotentes alogênicas em cães acometidos pela doença renal**. Medicina Veterinária (UFRPE), 13(4), 534–543, 2020. DOI: https://doi.org/10.26605/medvet-v13n4-3662

SANTOS E. J. C., MAZZEO, A. & BRAGA, C. L. **Potencial terapêutico de células progenitoras adultas multipotentes alogênicas no tratamento de aplasia medular secundária à erliquiose canina**, *Science and Animal Health*, 11(1), p. 35-52, 2023. DOI: https://doi.org/10.15210/sah.v11i1.24995

SANTOS E J C, MAZZEO A, BRAGA C L. **Study of the safety and therapeutic efficacy of multipotent adult progenitor cells in the treatment of feline asthma.**

ISSN 2674-8584

Received: 07/04/2026 - **Accepted:** 12/06/2026
Vol: 08.06
DOI: 10.66104/6mbt6042
Pages: 1-27

Research, Society and Development, 13(3), e2713340644, 2024a. DOI: https://doi.org/10.33448/rsd-v13i3.40644

SANTOS E J C, MAZZEO A, BRAGA C L. **Evaluation of the safety and therapeutic efficacy of multipotent adult progenitor cells in the treatment of canine bronchitis**. *Research, Society and Development*, *13*(4), e12713441499, 2024b. DOI: https://doi.org/10.33448/rsd-v13i4.41499

SANTOS E J C, MAZZEO A, BARNA F S, BRAGA C L. **Study of the safety and therapeutic efficacy of multipotent adult progenitor cells in the treatment of perianal fistula in dogs**. Research, Society and Development, v. 13, n. 8, p. e1913844682, 2024c. DOI: https://doi.org/10.33448/rsd-v13i8.44682.

SEBBAG L, KASS P H, MAGGS D J. **Reference values, intertest correlations, and test-retest repeatability of selected tear film tests in healthy cats**. *Journal of the American Veterinary Medical Association, 246(*4), 426-435, 2015. DOI: https://doi.org/10.2460/javma.246.4.426

SEBBAG, L., PESAVENTO, P. A., CARRASCO, S. E., REILLY, C. M., & MAGGS, D. J. **Feline dry eye syndrome of presumed neurogenic origin: a case report. *JFMS open reports*,** *4*(1), 2055116917746786, 2018. https://doi.org/10.1177/2055116917746786

UCCELLI, A., MORETTA, L., PISTOIA, V**. Mesenchymal stem cells in health and disease**. Nature reviews. Immunology, 8(9), 726–736, 2008. https://doi.org/10.1038/nri2395

UHL, L. K., SAITO, A., IWASHITA, H., MAGGS, D. J., MOCHEL, J. P., & SEBBAG, L. **Clinical features of cats with aqueous tear deficiency: a retrospective case**

RSV
ISSN 2674-8584

Received: 07/04/2026 - **Accepted:** 12/06/2026
Vol: 08.06
DOI: 10.66104/6mbt6042
Pages: 1-27

series of 10 patients (17 eyes). Journal of feline medicine and surgery, 21(10), 944–950, 2019. https://doi.org/10.1177/1098612X18810867

VILLATORO A J, FERNÁNDEZ V, CLAROS S, RICO-LLANOS G A, BECERRA J, ANDRADES J A. **Use of adipose-derived mesenchymal stem cells in keratoconjunctivitis sicca in a canine model**. *BioMed research international*, 527926, 2025. DOI: https://doi.org/10.1155/2015/527926

VILLATORO A J, HERMIDA-PRIETO M, FERNÁNDEZ V, FARIÑAS F, ALCOHOLADO C, RODRÍGUEZ-GARCÍA M I, MARIÑAS-PARDO L, BECERRA J. **Allogeneic adipose-derived mesenchymal stem cell therapy in dogs with refractory atopic dermatitis: clinical efficacy and safety**. The Veterinary record, 183(21), 654, 2018a. DOI: https://doi.org/10.1136/vr.104867

VILLATORO A J, CLAROS S, FERNÁNDEZ V, ALCOHOLADO C, FARIÑAS F, MORENO A, BECERRA J, ANDRADES J A. **Safety and efficacy of the mesenchymal stem cell in feline eosinophilic keratitis treatment.** *BMC veterinary research*, *14*(1), 116. 2018b. https://doi.org/10.1186/s12917-018-1413-4

WILLIAMS, D. L. **Immunopathogenesis of keratoconjunctivitis sicca in the dog**. *Veterinary Clinics of North America: Small Animal Practice*, 38(2), 251-268, 2008.

WANG Y, YI H, SONG Y. **The safety of MSC therapy over the past 15 years: a meta-analysis**. Stem Cell Res Ther. 12(1):545, 2021. doi: 10.1186/s13287-021-02609-x.

WEI L N, WU C H, LIN C T, LIU I H. Topical applications of allogeneic adipose-derived mesenchymal stem cells ameliorate the canine keratoconjunctivitis

ISSN 2674-8584

Received: 07/04/2026 - **Accepted:** 12/06/2026
Vol: 08.06
DOI: 10.66104/6mbt6042
Pages: 1-27

sicca. BMC veterinary research, 18(1), 217, 2022. DOI: https://doi.org/10.1186/s12917-022-03303-7

WOODHAM-DAVIES S. **Keratoconjunctivitis sicca in dogs**. The Veterinary Nurse, 11(1):19-23, 2020. DOI: 10.12968/vetn.2020.11.1.19

XUE Z, LIAO Y, LI Y. **Effects of microenvironment and biological behavior on the paracrine function of stem cells**. Genes Dis. 11(1):135-147, 2023. doi:10.1016/j.gendis.2023.03.013